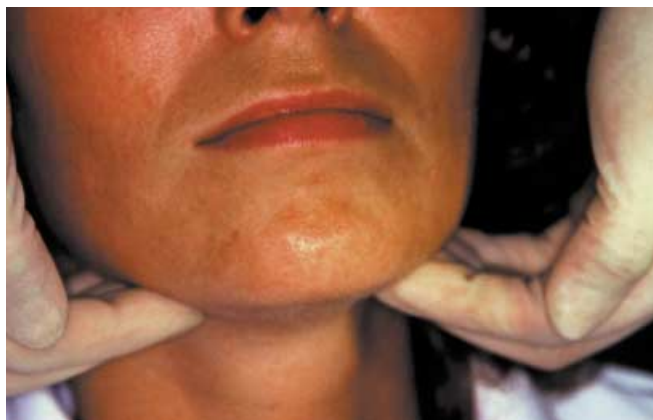

Perform a death-defying act

The 90-second oral cancer examination

A comprehensive oral cancer examination takes approximately 90 seconds and includes a review of the patient's medical and dental history, extraoral and intraoral inspections of the head and neck, and manual palpation of related specific sites.

The following review of an oral cancer examination is based on the standardized oral examination method recommended by the World Health Organization. It also is available in poster form from the National Institute of Dental and Craniofacial Research.¹

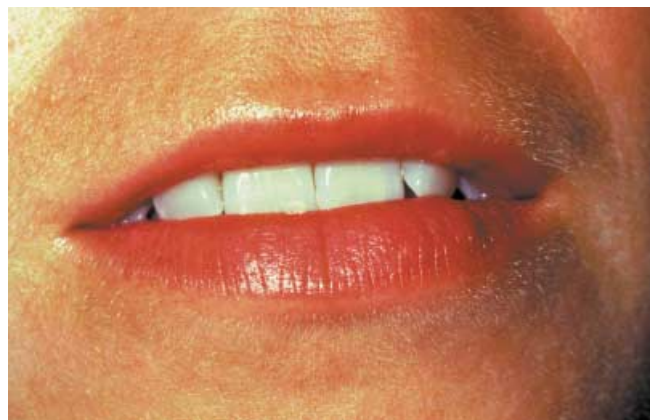

STEP 1. EXTRAORAL EXAMINATION

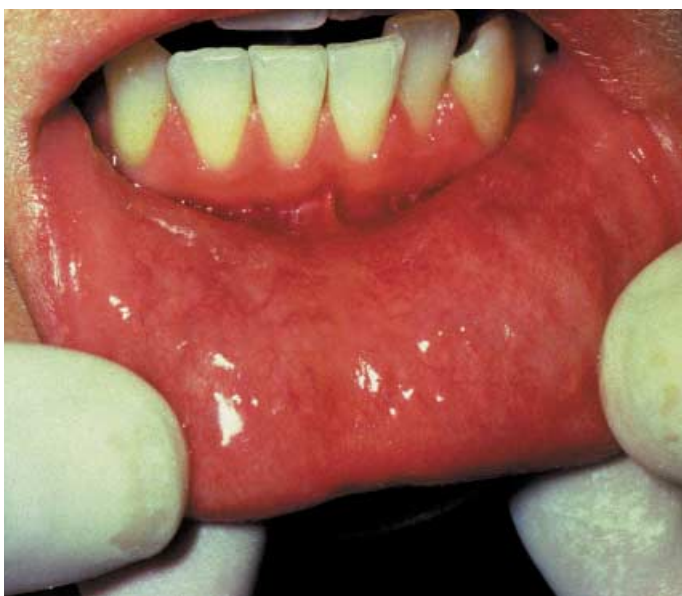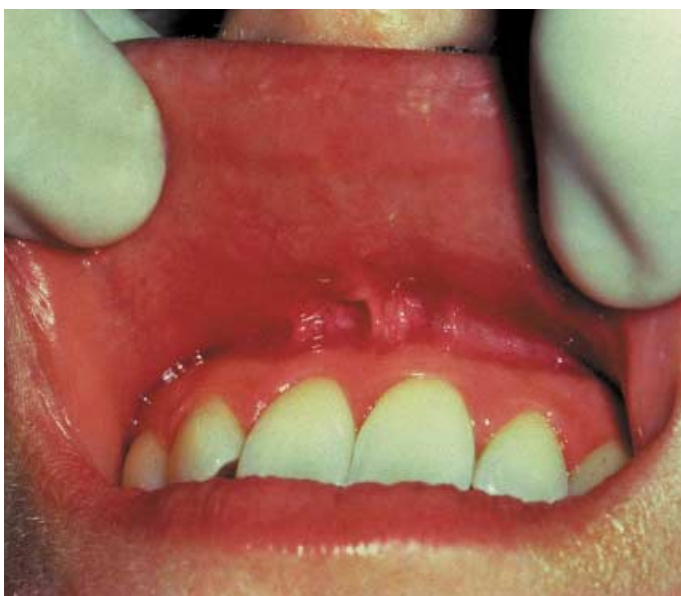The extraoral assessment includes an inspection of the face, head and neck with special attention to patients who appear to spend a lot of time in the sun. Note any asymmetry or lesions on the skin such as crusts, fissuring and growths. The regional lymph nodes in the submandibular and neck areas should be bilaterally palpated to detect any enlarged nodes; if enlargement is detected, assess their mobility and consistency.

STEPS 2-8. PERIORAL AND INTRAORAL SOFT-TISSUE EXAMINATION

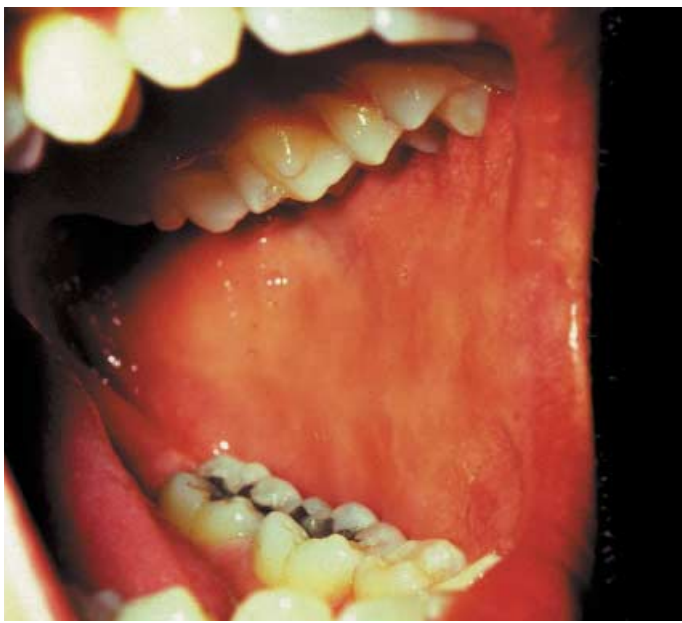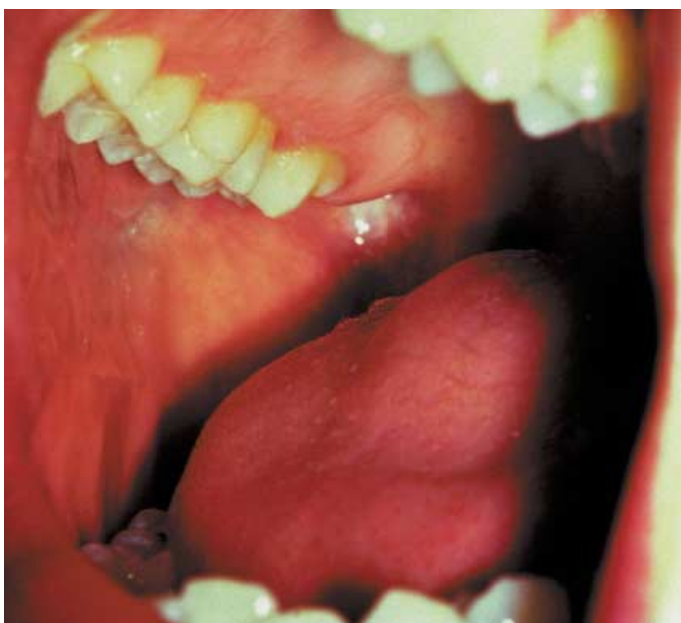A seven-step systematic assessment of the lips, labial mucosa, commissures and buccal mucosa, gingiva and alveolar ridges, tongue, floor of the mouth and palate is suggested. It requires adequate light, a mouth mirror and two 2 × 2-inch gauze squares.



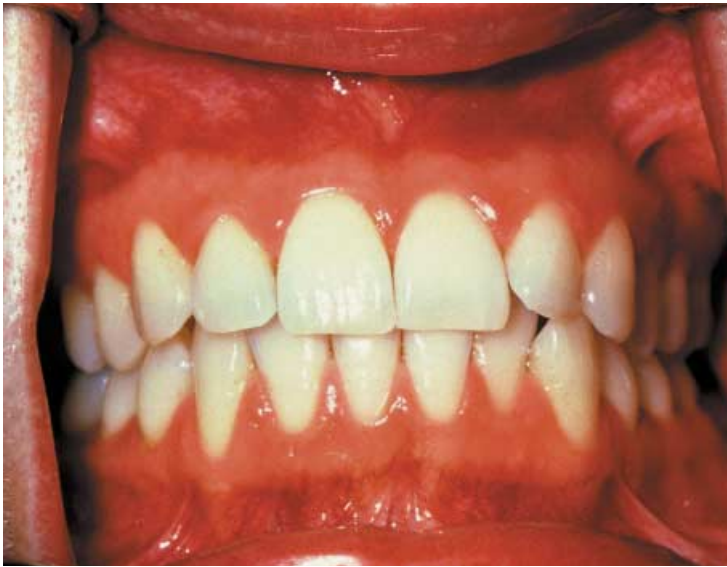2. Lips. Observe the lips with the patient's mouth both closed and open. Note the color, texture and any surface abnormalities of the vermillion borders.



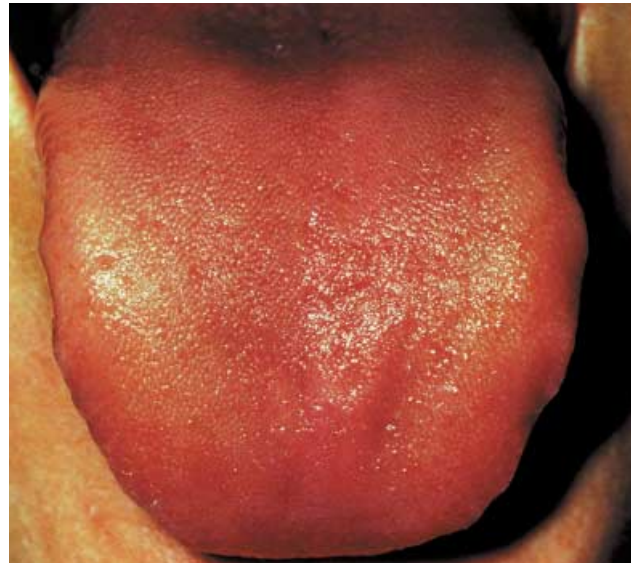3. Labial mucosa. With the patient's mouth partially open, visually examine the labial mucosa and sulcus of the maxillary vestibule and frenum, as well as the mandibular vestibule. Note the color, texture and any swelling or other abnormalities of the vestibular mucosa and gingiva.



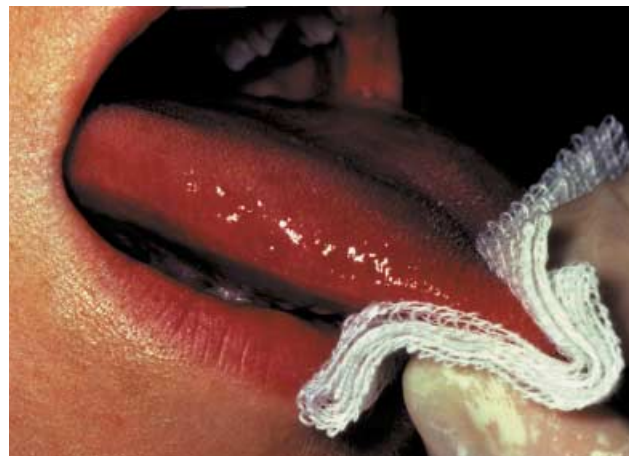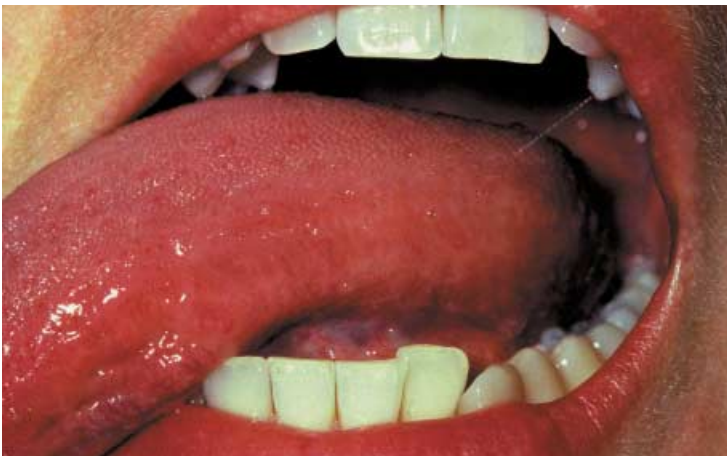4. Buccal mucosa. Retract the buccal mucosa. Examine first the right, then the left, buccal mucosa extending from the labial commissure and back to the anterior tonsillar pillar. Note any change in pigmentation, color, texture and other abnormalities of the mucosa. Examine the commissures carefully.



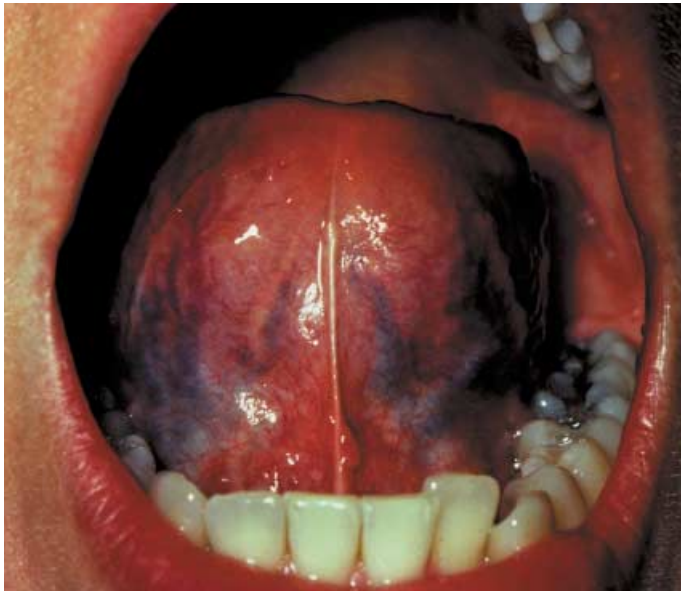5. Gingiva. Examine the buccal and labial aspects of the gingival and alveolar ridges by starting with the right maxillary posterior gingiva and alveolar ridge and then move around the arch to the left posterior area. Drop to the left mandibular posterior gingiva and alveolar ridge and move around the arch to the right posterior area. Then, examine the palatal and lingual aspects as on the facial side, from right to left on the palatal (maxillary) aspect and left to right on the lingual (mandibular) aspect.



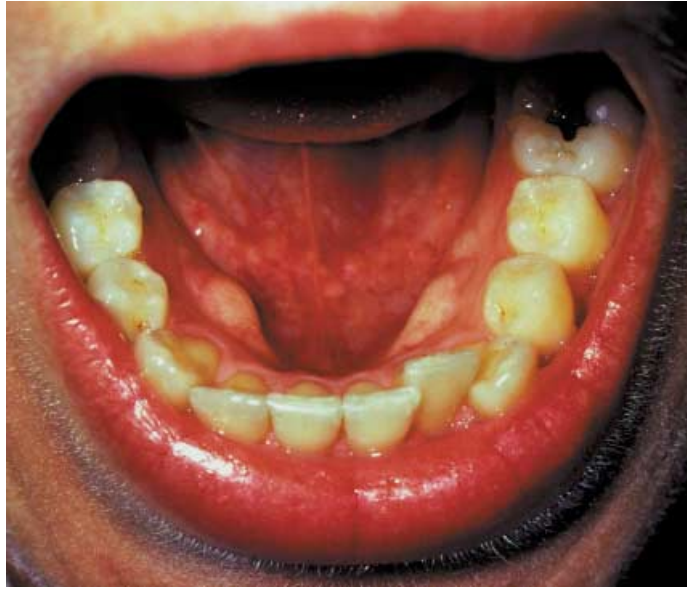
6. Tongue. With the patient's tongue at rest and mouth partially open, inspect the dorsum of the tongue for any swelling, ulceration or variation in size, color or texture. Ask the patient to protrude his or her tongue and examine it for any abnormality of mobility or positioning.



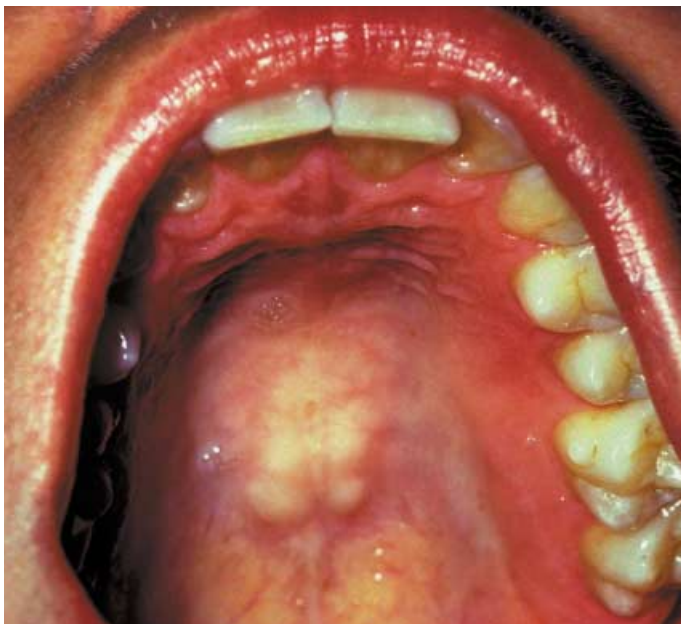
Grasp the tip of the tongue with a piece of gauze to assist in full protrusion of the tongue. Use a mouth mirror to visually assess the more posterior aspects of the tongue's lateral borders and to retract the cheek. Also, gently run your index finger along the lateral borders of the tongue to feel for any hard tissues.



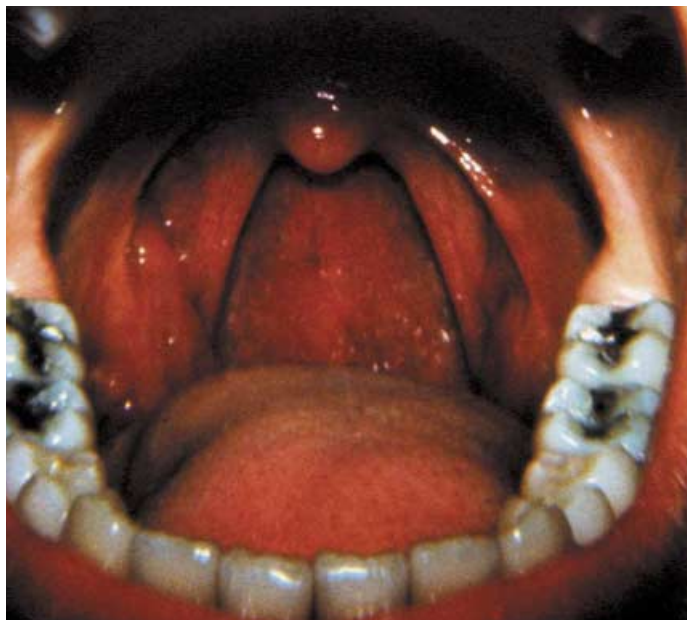
Then examine the ventral surface. Palpate the tongue to detect growths. The tongue should feel soft and pliable.

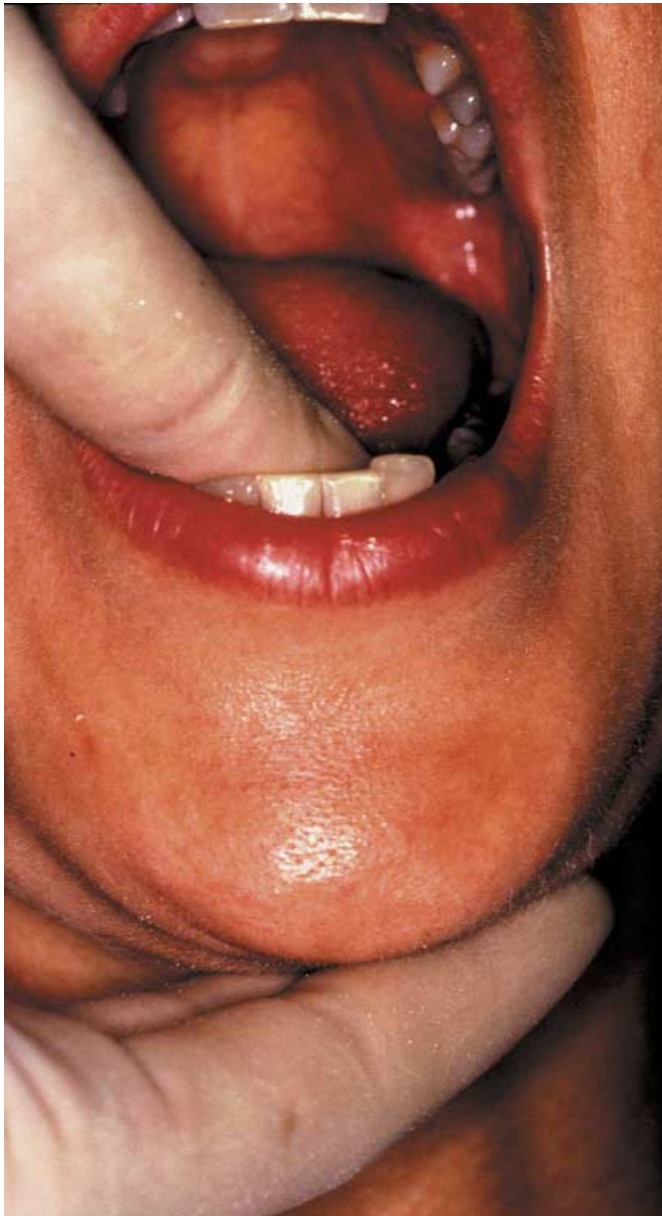

7. Floor of the mouth. With the tongue still elevated, inspect the floor of the mouth for changes in color, texture, swellings or other surface abnormalities. Irregularities are more easily detected if gauze is used to wipe the floor of the mouth dry; the gauze also can be used to keep the tongue out of the way.



8. Palate. With the patient's mouth wide open and head tilted back, gently depress the base of the tongue with a mouth mirror. Inspect the hard and soft palates.





Bimanually palpate the floor of the mouth for any abnormalities. All mucosal or facial tissues that seem to be abnormal should be more carefully palpated.

CONCLUSION

An oral cancer examination, which is part of a comprehensive oral examination, takes only about 90 sec-

POINTS TO REMEMBER WHEN SCREENING FOR ORAL CANCER.

- Most oral cancers are located on the lateral borders of the tongue, floor of the mouth and lips—special attention should be focused in these areas.
- Tell your patient what you are doing with each procedure and why.
- Always note any changes in color and texture of all soft tissues or any swelling. If you detect an abnormality, determine the history of the lesion; if the abnormality has been of more than two weeks' duration, take appropriate action to obtain a biopsy.²
- Follow up to ensure a definitive diagnosis of an abnormality.
- Teach your patients about the signs and symptoms of oral cancer.
- If a patient uses tobacco products, provide appropriate counseling or refer patient for counseling.³
- Remove all removable prostheses before starting the examination.

onds. All adult patients should receive this part of a comprehensive oral examination on a routine basis. All lesions that have not resolved within two weeks of manifestation warrant a biopsy or referral to an appropriate provider. Special points to remember when screening for oral cancer are listed in the box ("Points to Remember When Screening for Oral Cancer"). ■

Address reprint requests to Alice M. Horowitz, Ph.D., senior scientist, National Institute of Dental and Craniofacial Research, National Institutes of Health, Building 45, Room 3AN-44B, Bethesda, Md. 20892-6401.

Photos courtesy of Joseph Konzelman, D.D.S.

1. Detecting oral cancer: A guide for health professionals. Bethesda, Md.: National Institutes of Health, National Institute of Dental and Craniofacial Research; 1995. Available at: "www.nohic.nidcr.nih.gov/pubs/detect". Accessed Sept. 25, 2001.

2. Sciubba JJ. Oral cancer and its detection: history-taking and the diagnostic phase of management. *JADA* 2001;132(supplement):12S-5S.

3. Tomar SL. Dentistry's role in tobacco control. *JADA* 2001;132(supplement):30S-5S.